

Multidisciplinary Treatment Approach of a Patient with Amelogenesis Imperfecta Superimposed by Thumb Sucking Habit: A Case Report

Raed R. Gholman¹, BDS, SBPD, and Omar A. El Meligy^{2,3}, MSc, PhD

¹King Abdulaziz Medical City, Jeddah, Saudi Arabia

²Department of Pediatric Dentistry, Faculty of Dentistry, King Abdulaziz University, Jeddah, Saudi Arabia

³Faculty of Dentistry, Alexandria University, Alexandria, Egypt

Correspondence

Prof. Omar A. El Meligy
P.O. Box 80209, Jeddah 21589
Saudi Arabia
e.M: omeligy@kau.edu.sa

Submission: 14 August 2017

Accepted: 30 August 2017

Citation

Gholman RR, El Meligy OE. Multidisciplinary treatment approach of a patient with amelogenesis imperfecta superimposed by thumb sucking habit: a case report. JKAU Med Sci 2017; 24 (4): 31-39. DOI: 10.4197/Med. 24.4.5

Abstract

A seven-year-old boy was presented with discontent of his teeth appearance, mild teeth sensitiveness, bad masticatory effectiveness, difficulty in speech and low self-esteem. The clinical and radiographic results indicated amelogenesis imperfecta. Because of uncooperative behavior, treatment was accomplished under general anesthesia. The use of composite resin and stainless steel crowns produced effective and satisfying improvement of the patient's aesthetic looks, in addition to prevention of further sensitivity and wear so enhancing his functional needs. The lastingness of the thorough management of this patient needed powerful stress on careful oral hygiene. There is a major role of multidisciplinary team to the effective management of patients with hypomaturational type of amelogenesis imperfecta. Many factors have a significant part in treatment planning of amelogenesis imperfecta cases such as patient's age, socioeconomic condition, seriousness of the defect, the patient's collaboration and association with other medical conditions.

Keywords

Amelogenesis imperfecta; Thumb sucking habit; Stainless steel crowns; Composite resin

Introduction

Amelogenesis imperfecta (AI) is a congenital disorder that interferes with normal enamel formation in the absence of a systemic disorder. Generally, it affects most or all of the teeth in both the primary and permanent dentitions^[1]. Amelogenesis imperfecta may be inherited by x-linked or sporadic inheritance. The different clinical manifestations of AI have a specific gene anomaly associated with each phenotype. Specific mutations proven to cause AI

include: amelogenin (AMELX), enamelin (ENAM), kallikrein4 (KLK4), enamelysis (MMP-20) and FAM83H^[2]. Although AI is an uncommon pathological dental defect (its prevalence extends from 1 in 2000 up to 1 in 18,000 patients)^[3], its classification, causes, clinical and treatment features have been discussed considerably in the scientific publications. The cause and effect association of atypical dentoskeletal features is of major value for the clinician in AI patients, particularly in open bite cases.

The generally recognized classification of AI comprises three forms: hypocalcified (normal thickness, smooth surface, less hardness), hypoplastic (reduced thickness, smooth surface, normal hardness) and hypomaturation (normal thickness, chipped surface, less hardness, opaque white coloration)^[4]. Classification depends mostly on many factors, such as phenotypical malformations and molecular defects, mode of inheritance, biochemical examination of the enamel and not only the clinical aspect of the enamel^[5]. In most of the studies, the number of AI subtypes referred to is 12^[6]. So far, at least 15 forms of AI have been reported based on clinical features and inheritance pattern^[7].

Case Report

A seven year-old uncooperative Saudi boy (Fig. 1) was referred to King Abdulaziz Medical City (KAMC) dental clinics from a primary health care center presented with dissatisfaction of his teeth appearance, mild posterior teeth sensitivity, poor masticatory efficiency, difficulty in speech and low self-esteem. He was referred to pediatric ophthalmologist, orthopedic and nephrologist to rule out any medical conditions, and cleared for treatment under general anesthesia (GA) with no special considerations except for feet toes syndactyly which will be surgically separated later.

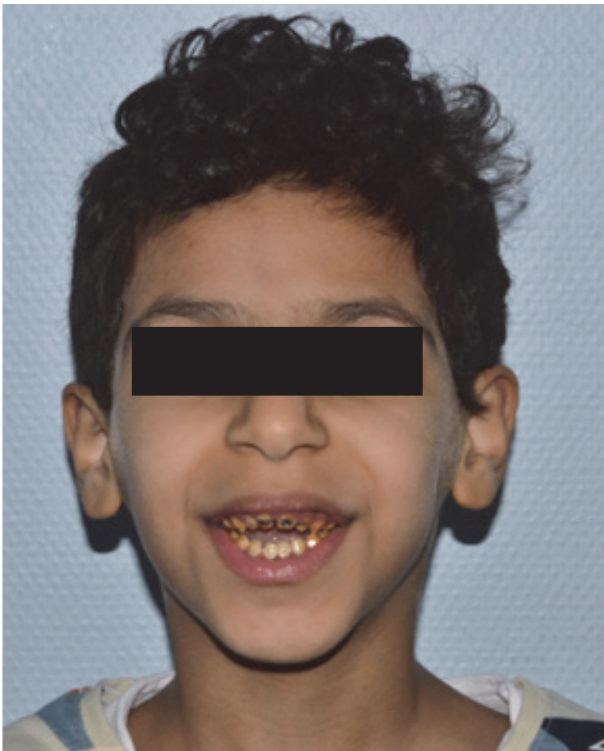

Figure 1. Extra-oral picture of the patient.

Extra-oral examination revealed long face, feet syndactyly (Fig. 2) and indentation on his thumb due to thumb sucking habit (Fig. 3). Intra-oral clinical (Fig. 4) and radiographic (Fig. 5 and 6) examination revealed bad oral hygiene with excessive plaque and calculus deposition, which caused generalized gingivitis. Teeth exhibited short clinical crowns with wide areas of thin, yellow, brown or grey, hypoplastic and chipped enamel

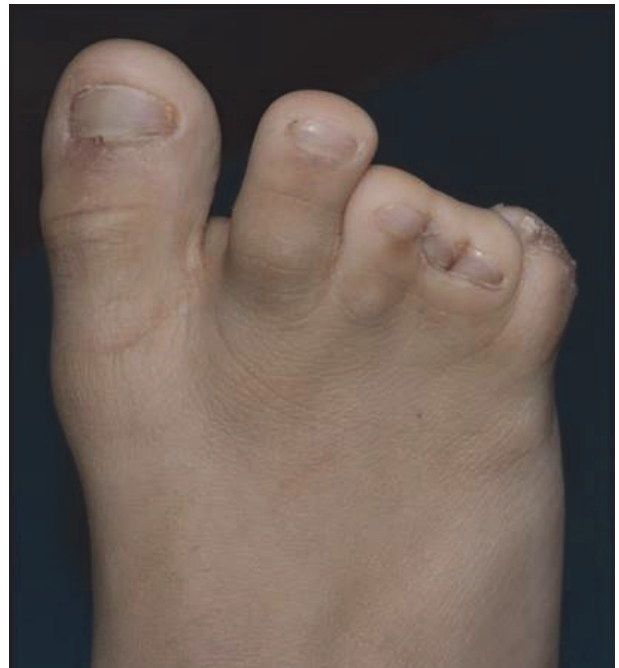


Figure 2. Foot syndactyly.

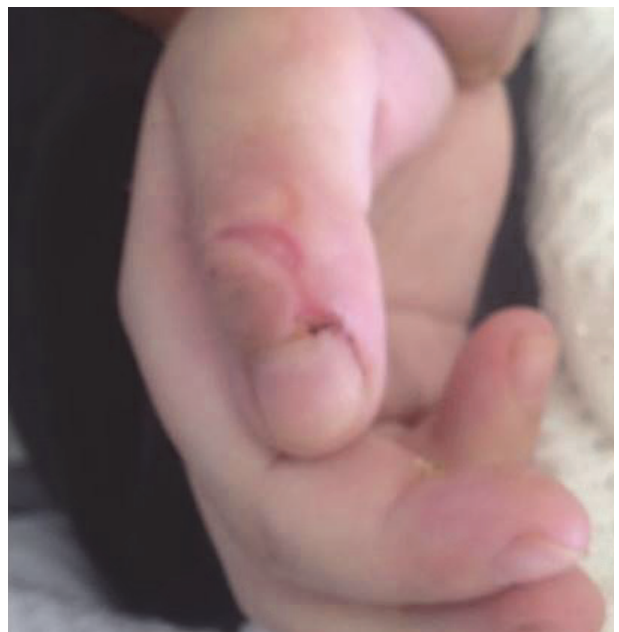

Figure 3. Thumb injury.

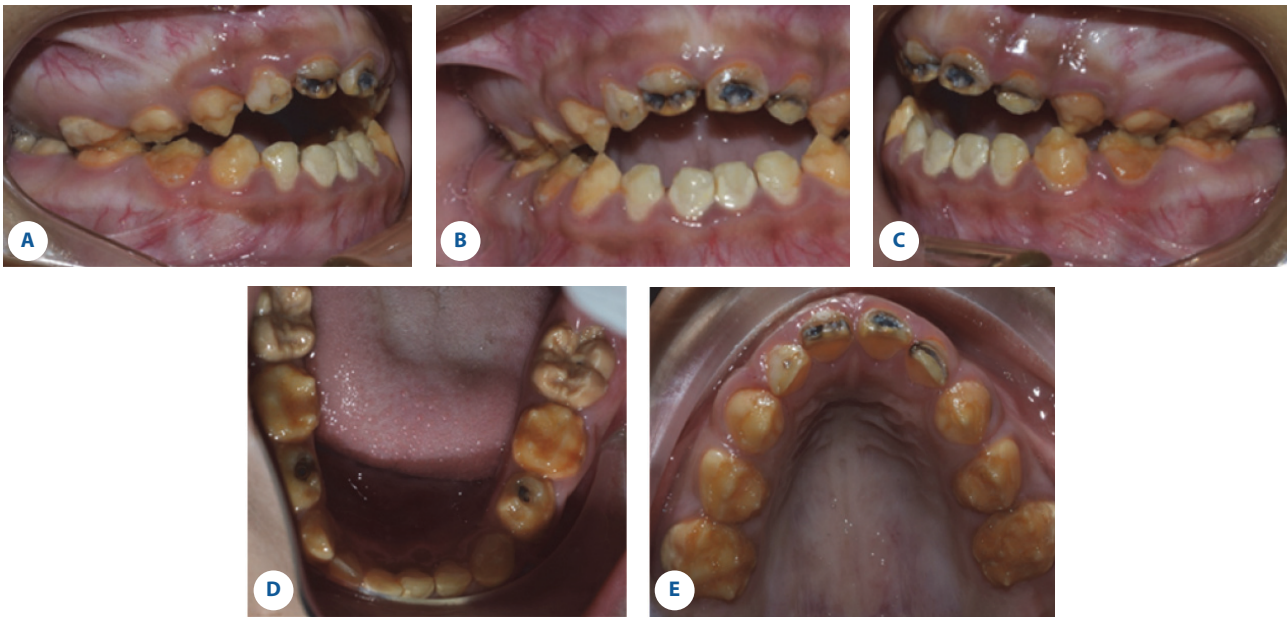

Figure 4A-E. Intra-oral preoperative clinical pictures of affected teeth.

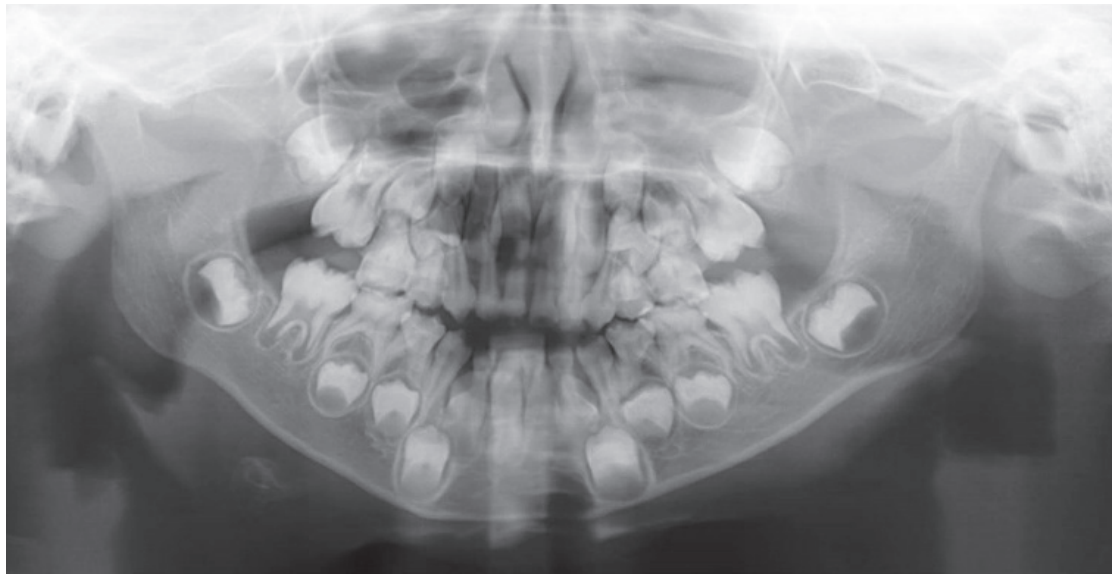

Figure 5. Pre-operative panoramic radiograph.

as well as exposed dentin in posterior teeth and dental caries.

Early loss of vertical dimension, in addition to an open bite of 15 mm and an over jet of 1 mm, constricted maxilla and bilateral posterior cross bite were evident. A mesial step primary molar relationship with class II canine relationship. The first panoramic, cephalogram, bitewing and periapical radiographic examination (Fig. 5, 6 and 7), revealed an early permanent dentition

period, with all permanent teeth present and covered by thin layer of enamel. The underlying dentin-pulp complex seemed normal. The dental age of this patient is late compared to his chronologic age.

Discussion

The clinical and radiographic results indicated a hereditary enamel disorder *i.e.*, AI depending on the Witkop's classification^[8], diagnosis of hypomaturation

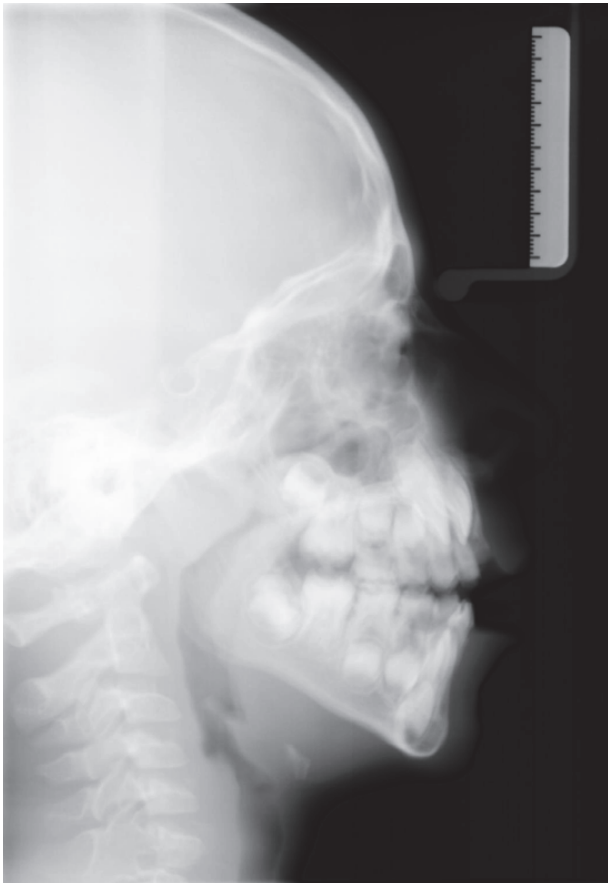

Figure 6. Pre-operative cephalogram.

type of AI was done. Caries risk was evaluated by interviewing the parents and patient concerning oral hygiene, diet and general lifestyle habits. The patient was categorized as a high-risk group by the evaluation, depending on several predisposing factors, with AI the most important of all.

Multidisciplinary approach for best treatment outcomes was accomplished with multiple treatment alternatives that have been suggested in the literature. Alternatives varied from simple microabrasion^[9], to resin-based composites^[10] and Stainless steel crowns (SSCs)^[11]. All ceramic crowns^[12], metal-ceramic crowns^[13], and veneers^[14] might be considered in the future upon eruption of permanent dentition. Several case reports have concentrated on the early treatment of children and adolescents, and the utilization of bonded restorations has increased popularity because of numerous advantages associated with these materials; conservative approach, superior aesthetics and enhanced wear make their use favorable^[10,11].

Pediatric dentists, prosthodontics and orthodontics contributed in treatment planning. The primary objective of treatment was to provide restorations for the preservation of remaining tooth structure against further sensitivity and wear. Restoration of anterior teeth with composite resin to enhance the patients' aesthetic, in addition to full coverage of posterior primary and permanent molars with SSCs and extraction of exfoliating primary teeth was the ideal treatment option at this time. Orthodontic consultation was done regarding the open bite and the treatment aim was to break the habit in addition to maxillary expansion to correct the posterior cross bite and open bite either by rapid or slow palatal expanders with the superiority to slow palatal expander due to the possibility of combining two appliances together to correct both maxillary constriction and open bite.

Prior to treatment, a written informed consent was obtained from the parents.

The sequence of treatment accomplished under GA was as follows:

1. Composite resin in affected anterior teeth. Five percent sodium hypochlorite (NaClO) solution was applied for one minute on the tooth structure to enhance bonding between composite restoration and tooth structure^[15].
2. Ferric sulfate pulpotomy in teeth #74 and #84.
3. SSCs in posterior primary and permanent molars.
4. Extraction of anterior exfoliating carious teeth #51, #61, #71, #72, #81 and #82.
5. Impressions were taken to construct orthodontic casts.
6. The patient was given instructions regarding thumb sucking habit effects on dentofacial structures post-operatively in the pediatric ward.

In the 3 months' recall, patient cooperation was gained once more using tell-show and do (TSD), positive reinforcement and rewarding approaches with a positive history of thumb sucking habit.

The following procedures were done:

1. Bands selection and impressions were taken to construct a versatile modified quad-helix appliance. The appliance was constructed using a 0.036-inch stainless wire incorporating palatal

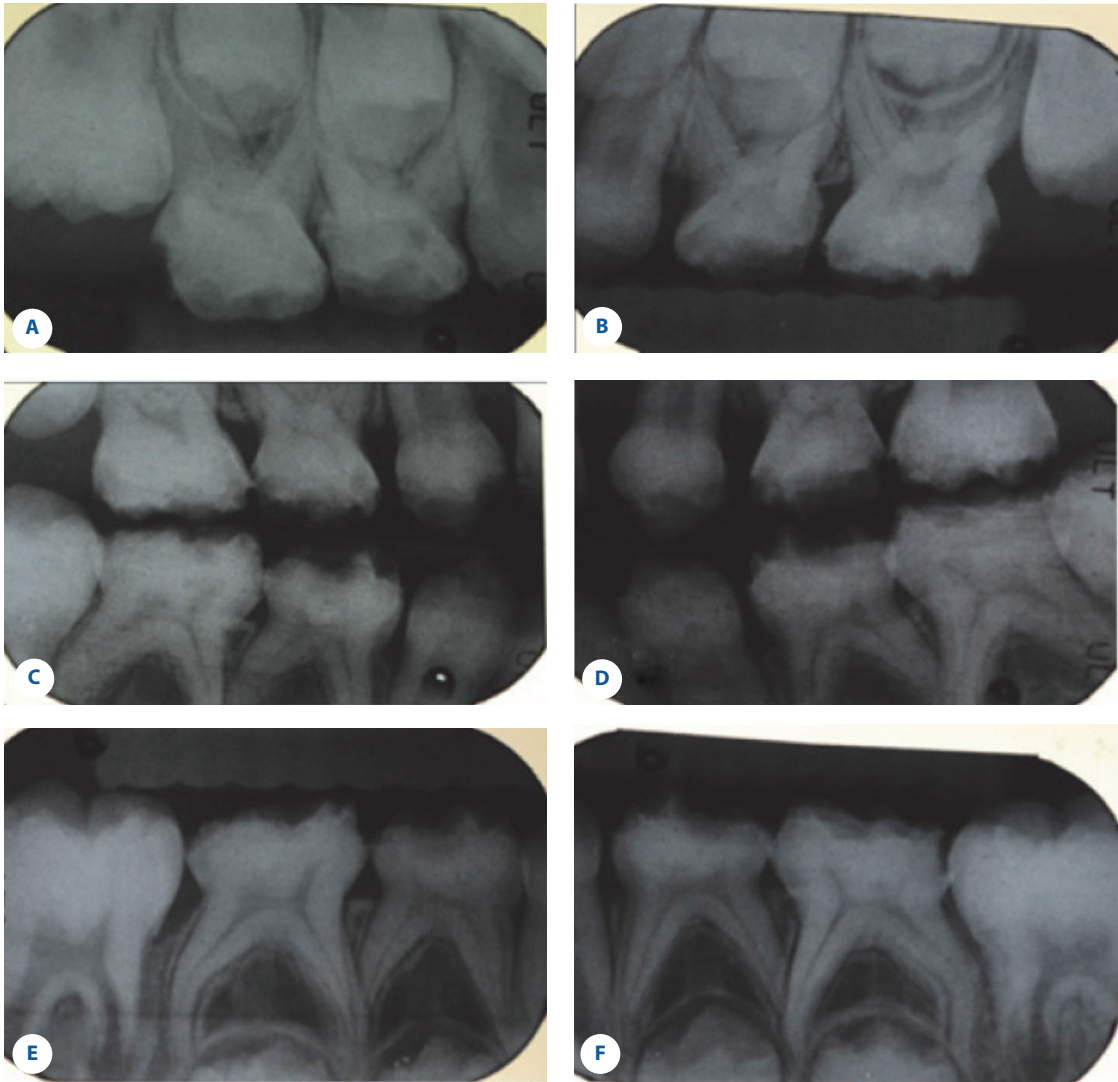


Figure 7A-F. Pre-operative periapical and bitewing views.

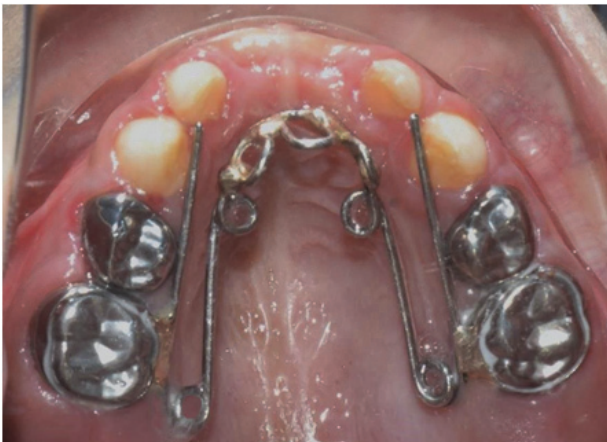

Figure 8. Insertion of a versatile modified quad-helix appliance.

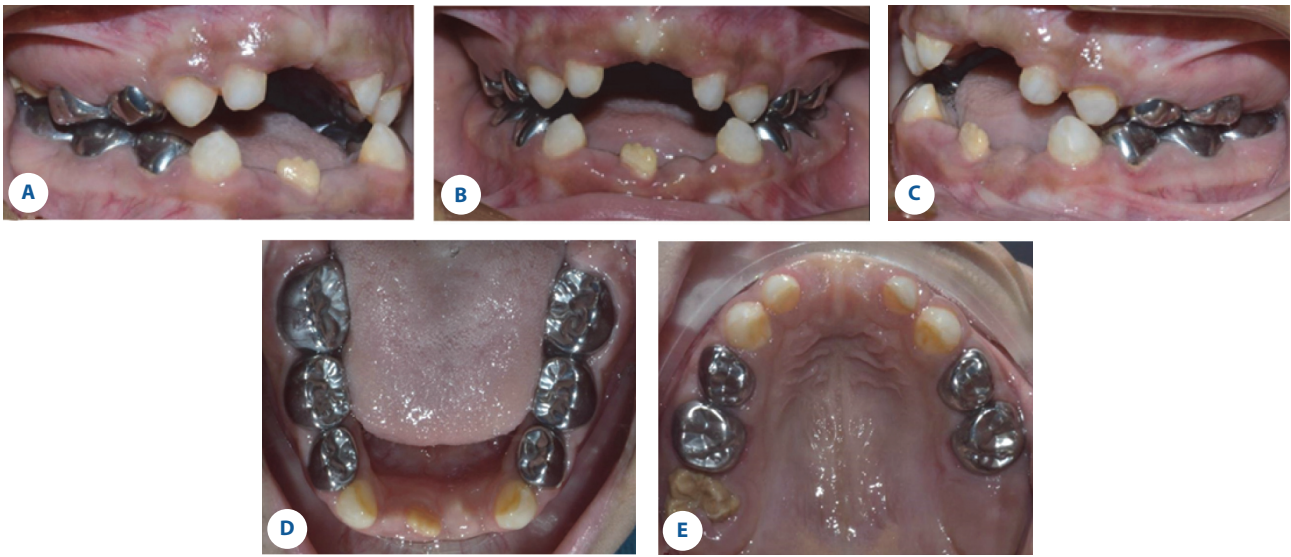

Figure 9A-E. Three months' post-operative clinical pictures.

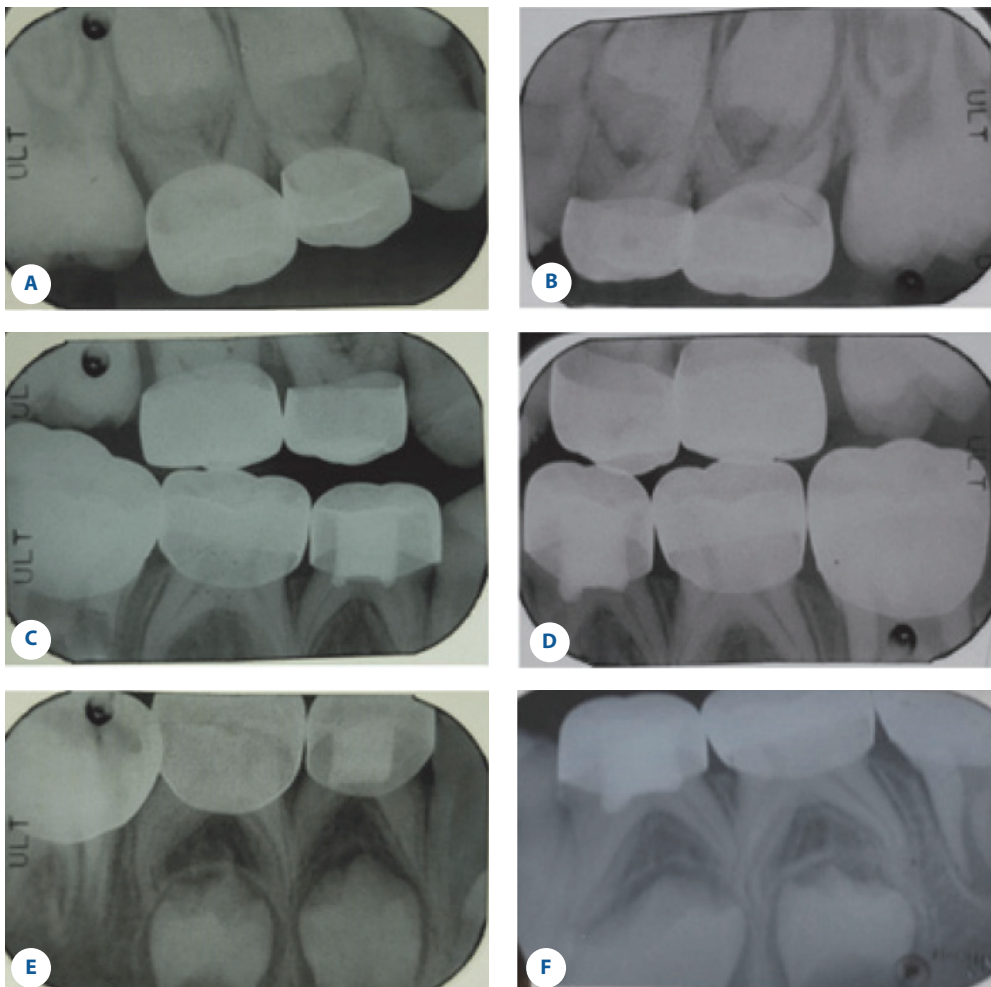


Figure 10A-F. Three months' post-operative radiographs.

cribs. The wire component with the cribs was soldered to the bands on primary second molars.

2. Prophy and fluoride application using 5% sodium fluoride (NaF) was done.
3. Oral hygiene instructions were reinforced.
4. The appliance was cemented using glass ionomer cement (GC Fuji 1) (Fig. 8), then the patient was followed-up once every month to assess oral hygiene, compliance, appliance efficiency and to activate the quad-helix.

After 3 months, parents were satisfied reporting that their son discontinued the habit and they noticed a change in his facial as well as dental appearance. Upon clinical examination, posterior cross bite was corrected successfully with reduced open bite, but still not the optimal so, the appliance was kept as a habit breaking device without activation and the patient was still under treatment. The use of resin-based composites and SSCs produced effective and satisfying improvement of the patient's aesthetic looks, in addition to prevention of further sensitivity and wear so enhancing his functional needs. All the restorations are intact with no signs of fracture, staining, cracking, or dental caries (Figs. 9 and 10). Oral hygiene improved during recall visits and the gingival tissue healed with no inflammation.

Conclusions

The following conclusions can be made:

1. There is a major role for the multidisciplinary team in the effective management of patients with hypomaturation type of AI.
2. Many factors have a significant part in treatment planning of AI cases such as patient's age, socioeconomic condition, seriousness of the defect, the patient's collaboration and association with other medical conditions.
3. Medical screening is important in AI cases due to association of AI with many conditions such as bicytopenia, or platyspondyly.

Conflict of Interest

The authors had no conflict of interest.

Disclosure

The authors did not receive any type of commercial support either in forms of compensation or financial

for this study. The author has no financial interest in any of the products or devices, or drugs mentioned in this article.

Ethical Approval

Obtained.

References

- [1] Wright JT, Torain M, Long K, Seow K, Crawford P, Aldred MJ, Hart PS, Hart TC. Amelogenesis imperfecta: Genotype-phenotype studies in 71 families. *Cells Tissues Organs* 2011; 194: 279-283.
- [2] Backman B, Holmgren G. Amelogenesis imperfecta: A genetic study. *Hum Hered* 1998; 38: 189-206.
- [3] Stern BM. A multidisciplinary approach to the functional and esthetic rehabilitation of amelogenesis imperfect and open bite deformity: A case report. *J Esthet Restor Dent* 2010; 22: 282-293.
- [4] Lindemeyer RG, Gibson CW, Wright TJ. Amelogenesis imperfecta due to a mutation of the enamelin gene: Clinical case with genotype-phenotype correlations. *Pediatr Dent* 2010; 32: 566-570.
- [5] Pavlič A, Battelino T, Podkrajsek KT, Ovsenik M. Craniofacial characteristics and genotypes of amelogenesis imperfecta patients. *Eur J Orthod* 2001; 33: 325-331.
- [6] Winter GB, Brook AH. Enamel hypoplasia and anomalies of the enamel. *Dent Clin North Am* 1997; 19: 324.
- [7] de La Dure-Molla M, Philippe Fournier B, Berdal A. Isolated dentinogenesis imperfecta and dentin dysplasia: revision of the classification. *Eur J Hum Genet* 2015; 23: 445-451.
- [8] Witkop CJ Jr. Amelogenesis imperfecta, dentinogenesis imperfecta and dentin dysplasia revisited: problems in classification. *J Oral Pathol* 1998; 17: 547-553.
- [9] Rodd HD, Abdul-Karim A, Yesudian G, O'Mahony J, Marshman Z. Seeking children's perspectives in the management of visible enamel defects. *Int J Paediatr Dent* 2011; 21: 89-95.
- [10] Markovic D, Petrovic B, Peric T. Case series: clinical findings and oral rehabilitation of patients with amelogenesis imperfecta. *Eur Arch Paediatr Dent* 2010; 11: 201-208.
- [11] Sabatini C, Guzman-Armstrong S. A conservative treatment for amelogenesis imperfecta with direct resin composite restorations: a case report. *J Esthet Restor Dent* 2009; 21: 161-169.
- [12] Gisler V, Enkling N, Zix J, Kim K, Kellerhoff NM, Mericske-Stern R. A multidisciplinary approach to the functional and esthetic rehabilitation of amelogenesis imperfecta and open bite deformity: a case report. *J Esthet Restor Dent* 2010; 22: 282-293.
- [13] Bharath Shetty Y, Shetty A. Oral rehabilitation of a young adult with amelogenesis imperfecta: a clinical report. *J Indian Prosthodont Soc* 2010; 10: 240-245.

Multidisciplinary Treatment Approach of a Patient with Amelogenesis Imperfecta Superimposed by Thumb Sucking Habit...
R.R. Gholman and O.A. El Meligy

- [14] Ramos AL, Pascotto RC, Iwaki Filho L, Hayacibara RM, Boselli G. Interdisciplinary treatment for a patient with open-bite malocclusion and amelogenesis imperfecta. *Am J Orthod Dentofacial Orthop* 2011; 139: S145-S153.
- [15] Venezia RD. Enamel pretreatment with sodium hypochlorite to enhance bonding in hypocalcified amelogenesis imperfecta: case report and SEM analysis. *Pediatr Dent* 1994; 16: 433-436.

نهج العلاج متعدد التخصصات لمريض نقص النشوء مترابك بعادة مص الإبهام: تقرير حالة

رائد رأفت غلمان^١ وعمر عبد الصادق المليجي^{٢،٣}

^١مدينة الملك عبد العزيز الطبية بالحرس الوطني

^٢قسم طب اسنان الاطفال، كلية طب الأسنان، جامعة الملك عبد العزيز

جدة - المملكة العربية السعودية

^٣كلية طب الأسنان، جامعة الإسكندرية

الإسكندرية - مصر

المستخلص. صبي يبلغ من العمر سبع سنوات قدم مع عدم الرضا من ظهور أسنانه، حساسية أسنان خفيفة، ضعف كفاءة المضغ، صعوبة في الكلام وانخفاض احترام الذات. أشارت النتائج السريرية والإشعاعية إلى نقص النشوء. وبسبب السلوك غير المتعاون، تم إنجاز العلاج تحت التخدير العام. أدى استخدام الراتنج المركب وتيجان الاستئليس ستيل إلى تعزيز نجاح ومرضى للمظهر الجمالي للمريض، فضلاً عن الحماية من مزيد من التآكل والحساسية وبالتالي تحسين احتياجاته العملية. العلاج الشامل طويل المدى لهذا المريض يتطلب التركيز القوي على نظافة الفم الدقيق. هناك دور رئيسي من نهج متعدد التخصصات إلى العلاج الناجح للمرضى الذين يعانون من مرض نقص النشوء (نوع نقص الضج). العديد من العوامل يمكن أن تلعب دوراً هاماً في تخطيط العلاج لحالات نقص النشوء مثل عمر المريض، والوضع الاجتماعي والاقتصادي، وشدة الاضطراب، وتعاون المريض وعلاقته مع الحالات الطبية الأخرى.