

Transcutaneous Electric Nerve Stimulator Induced Inappropriate ICD Shock

Naeem Al-Shoaibi, MBBS, FRCP(C), ABIM

*Arrhythmia Services, Division of Cardiology
McMaster University and Hamilton Health Sciences
Hamilton, Ontario, Canada*

Abstract. Inappropriate shock delivered by implantable cardioverter defibrillators due to electromagnetic interference is a well-known phenomenon. This case report is about a new source of interference from a transcutaneous electronic nerve stimulation unit. Although the artifact from transcutaneous electronic nerve stimulation and interference with appropriate function of cardiac pacemakers is well documented, adverse interaction with implantable cardioverter defibrillators has rarely been reported. This case present a patient in whom a transcutaneous electrical nerve stimulation (a unit created an electrical artifact that was interpreted by a trans-venous implantable cardioverter defibrillators as ventricular fibrillation), led to the delivery of inappropriate therapy. Transcutaneous electrical nerve stimulation units should be used with caution in patients with implantable cardioverter defibrillators.

Keywords: In appropriate shocks, Implantable cardioverter defibrillators, Electromagnetic interference.

Introduction

Transcutaneous Electric Nerve Stimulator (TENS) has been used to treat pain with varying degrees of success^[1,2]. Transcutaneous electric nerve stimulator (TENS) units known to create a far-field potential that may cause over-sensing in cardiac pacemaker^[3,4]. Similar interaction may happen with implantable cardioverter defibrillators (ICDs). The present case study describes a patient in whom far-field potentials from a TENS unit triggered inappropriate shocks from an ICD.

Correspondence & reprint request to:

Dr. Naeem Al-Shoaibi
1708 Mickleboro Ugh Drive, London ON L8L 2X2
Canada

Accepted for publication: 18 February 2013. Received: 3 December 2012.

Case Report

A 68-year-old male patient received a dual chamber ICDs (Guidant VENTAK PRIZM® 2DR) for ischemic cardiomyopathy and sustained monomorphic ventricular tachycardia. Four years later, the patient underwent treatment under care of a chiropractor for sciatica pain. Without a prior consultation with the ICDs clinic, he was treated with low output TENS type of muscle stimulator. While receiving treatment patient experienced a ICDs shock. The electric pads used for the chiropractic treatment was placed in the sacral region and were well away from the ICDs generator.

Implantable cardioverter defibrillators interrogation revealed inappropriate shock due to electromagnetic interference. High frequency electromagnetic interference (EMI) could be seen in all the channels of the ICD tracing (Fig. 1).

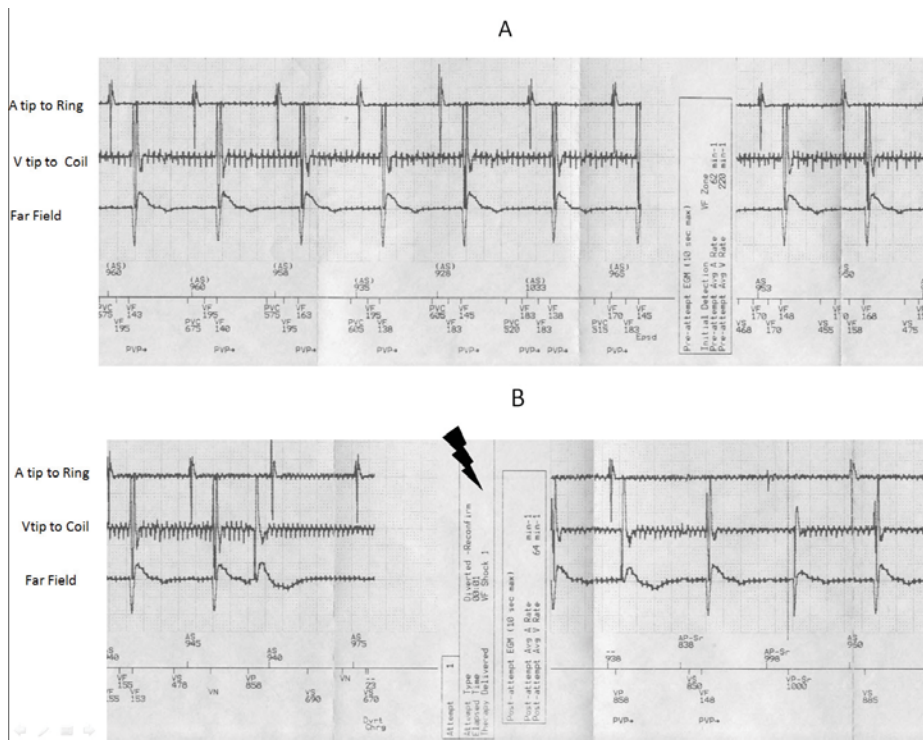


Fig. 1. A. ICD tracing showing features of electromagnetic interference from the chiropractic devices. All the channels (both near field and far field) show the artefacts: B. Delivery of inappropriate shock due to EMI.

Discussion

In theory, TENS stimuli could interfere with the pacemaker's generator, especially in the timing cycle^[5]. Yet, this has rarely been described clinically. The reported cases of interactions have resulted mainly during the synchronous pacemakers' over-sensing of TENS signals, resulting in the inhibition of stimuli to the heart. In 1978, Eriksson and her colleagues' reported the inability of synchronous pacemakers in four patients to distinguish TENS signals from spontaneous cardiac activity, resulting in complete inhibition of pacemaker stimuli. Recent reports showed that careful adjustment of the TENS energy vector allowed its application without inhibiting synchronous devices^[6]. The presence of a permanent pacemaker remains a relative contraindication to TENS therapy.

Electromagnetic interferences could cause false sensing in implantable defibrillators. The devices used in acupuncture, electrocautery, diathermy, electrolysis, and TENS can cause this problem. Patients with ICDs should be cautioned about these interferences and should avoid exposure to these sources.

References

- [1] **Robinson AJ.** Transcutaneous electrical nerve stimulation for the control of pain in musculoskeletal disorders. *J Ortho Sport Phys Ther* 1996; **24**(4): 208-226.
- [2] **Reev GF, Menon D, Corabian P.** Transcutaneous electrical nerve stimulation (TENS): A technology assessment. *Int J Technol Assess Health Care* 1996; **12**(2): 299-324.
- [3] **Eriksson M, Schüller H, Sjölund B.** Hazard from transcutaneous nerve stimulation in patients with pacemakers. *Lancet* 1978; **1**(8077): 1319.
- [4] **Chen D, Philip M, Philip PA, Monga TN.** Cardiac pacemaker inhibition by transcutaneous electrical nerve stimulation. *Arch Phys Med Rehabil* 1990; **71**(1): 27-30.
- [5] **Shade SK.** Use of transcutaneous electrical nerve stimulation for a patient with a cardiac pacemaker: A case report. *Phys Ther* 1985; **65**(2): 206-208.
- [6] **Rasmussen MJ, Hayes DL, Vlietstra RE, Thorsteinsson G.** Can transcutaneous electrical nerve stimulation be safely used in patients with permanent cardiac pacemakers? *Mayo Clin Proc* 1988; **63**(5): 443-445.

جهاز العصب المحفز يسبب الصعق الكهربائي غير المناسب من جهاز مزيل الرجفان المزروع

نعيم الشعبي

قسم كهربائية القلب، جامعة مكماستر

هاميلتون - كندا

المستخلص. من المعروف أن تداخل الإشارات الكهرومغناطيسية الخارجية قد تسبب الصدمة الكهربائية الخاطئة الصادرة من جهاز مزيل الرجفان المزروع. في هذه الحالة الخاصة نبين مصدر جديد للإشارات الكهرومغناطيسية الصادرة من جهاز محفز العصب الإلكتروني. حالات عدة بينت تأثير أجهزة العصب الإلكتروني على أجهزة تنظيم القلب ولكن تأثيره على أجهزة مزيل الرجفان نادر الحدوث. في هذه الحالة تم رصد تأثير التداخلات الكهرومغناطيسية على جهاز مزيل الرجفان مما أدى إلى حدوث صدمة كهربائية خاطئة للمريض أثر قراءة الجهاز لتلك التداخلات على إنها تسارع خبيث في بطين القلب.