

Upper Gastrointestinal Bleeding from Metastatic Testicular Embryonal Carcinoma

Jaudah A. Al-Maghrabi^{1,2} MD, FRCPC, FCAP and
Jamal M. Zekri³ MD, FRCP

¹*Department of Pathology,*

Faculty of Medicine, King Abdulaziz University

²*Departments of Pathology and* ³*Oncology.*

*King Faisal Specialist Hospital & Research Centre,
Jeddah, Saudi Arabia.*

jalmaghrani@hotmail.com

Abstract. In contrast to primary duodenal adenocarcinomas, germ cell tumors are potentially curable even when metastatic. It is therefore important for clinician and pathologist to be aware of this entity for management decision. A rare case of metastatic embryonal carcinoma, which initially was presented as upper gastrointestinal tract bleeding is reported. The patient was treated with 4 cycles of bleomycin, etoposide, and cisplatin and revealed a good response. In young men with a malignant tumor in the upper gastrointestinal tract, the diagnosis of germ cell tumors should be considered even in the absence of a palpable testicular mass.

Keywords: Germ cell tumor, Bleeding, Testicular neoplasm, Embryonal carcinoma.

Introduction

Testicular germ cell tumors (GCTs) metastasizing to the retroperitoneum rarely involve the upper gastrointestinal (GI) tract. Gastrointestinal hemorrhage as a complication of gastrointestinal (GI) tract is seen in less than 5% of GCTs^[1]. Few cases have been reported with GI bleeding as the initial presenting feature of metastatic GCTs^[1-4]. Abdominal masses

Correspondence & reprint request to: Prof. Jaudah A. Al-Maghrabi
P.O. Box 80205, Jeddah 21589, Saudi Arabia

Accepted for publication: 17 July 2011. Received: 03 June 2011.

and low-back pain have also been reported as presenting complaints^[2-4]. Although embryonal carcinoma is a dominant component in most of mixed GCTs metastasizing to GI tract^[5], pure embryonal metastatic embryonal carcinoma is exceedingly rare. This report is of a 21-year-old man who was presented with a 3 months history of intermittent melena, and 9 months history of low-back pain. He was confirmed to have a metastatic embryonal carcinoma of duodenum on an endoscopic biopsy.

Case History

A 21-year-old man was presented to the original referring hospital with a low-back pain for 9 months and melena for 3 months. The initial diagnosis was duodenal adenocarcinoma based on duodenal biopsy performed at another institution. Past medical history was not significant. The patient was referred to King Faisal Specialist Hospital & Research Centre for management. Physical examination revealed irregular epigastric mass. The remainder of his physical evaluation was normal. An upper GI endoscopy revealed a circumferential fungating ulcerating friable lesion involving the second and third parts of duodenum, and causing severe stenosis. CT scan revealed a soft tissue necrotic mass measuring 4.6 x 5 cm. The transverse dimensions involving the third part of the duodenum, encasing the aorta, displacing and compressing the inferior vena cava. The remainder of the small bowel appears grossly unremarkable. The rest of the abdominal, pelvic organs and chest are unremarkable. There was para-aortic lymph node measuring about 9.5 mm. No other mesenteric or pelvic lymph nodes were seen. Bone window appears unremarkable. Laboratory data revealed hemoglobin of 85 g/dL and platelet count $836 \times 10^9/\text{mL}$. His chemistry panel was normal. Tumor markers were within normal limits and include Carcinoembryonic antigen (CEA), 0.4 ug/L, Alfa fetoprotein (AFP), 1 ng/mL and beta human chorionic gonadotrophin (β -HCG), < 2 mIU/ml).

Pathological evaluation of the endoscopic duodenal biopsy revealed a malignant neoplasm composed of solid sheets, and nests of large primitive cells with amphophilic cytoplasm and numerous mitotic figures (Fig. 1a and 1b). Immunohistochemistry evaluation showed that the tumor cells were positive staining for Pankeratin, PLAP, OCT-4 and CD30 (Fig. 1c and 1d). They were focally positive for CK7. They were negative for epithelial membrane antigen (EMA), cytokeratins 20

(CK20), chromogranin, synaptophysin and thyroid transcription factor-1 (TTF-1). The diagnosis was made as a germ cell tumor composed of embryonal carcinoma. There was no other germ cell component in the biopsy. Based on this, scrotal ultrasound was performed and revealed highly suspicious ill-defined hypoechoic lesion on the upper pole of the right testicle, measuring around 1.0 x 1.2 cm. This lesion most likely represented the primary tumor.

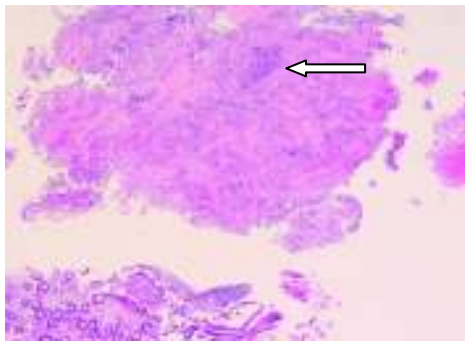


Fig. 1a. Microscopic section of duodenal biopsy revealing a fragment of granulation tissue (top) that contains small sheet of malignant cells (white arrow) surrounded by demoplastic reaction (hematoxylin-eosin, original magnifications X40).

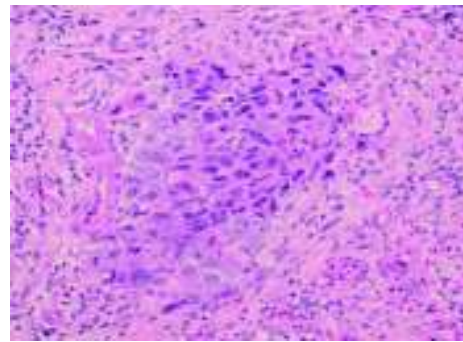


Fig. 1b. Higher power magnification showing the tumor sheet (hematoxylin-eosin, original magnifications X400).

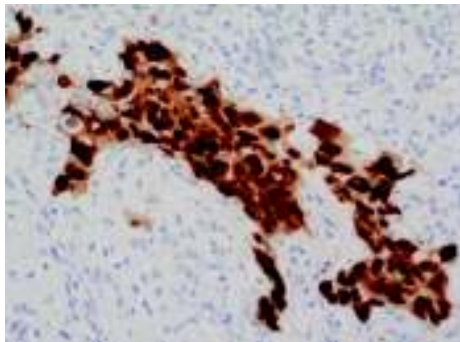


Fig. 1c. Immunohistochemistry stain for OCT-4 showing strong nuclear positivity staining (original magnifications X400).

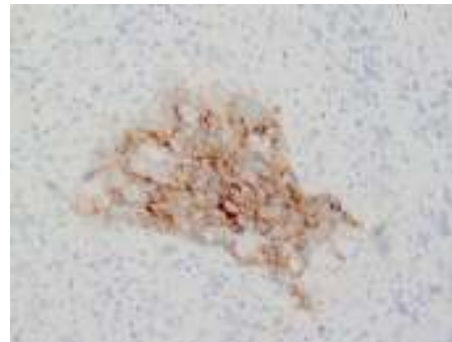


Fig. 1d. CD30 stain revealing positive membranous staining (original magnifications X400).

The patient was treated with 4 cycles of bleomycin, etoposide, and cisplatin (BEP), according to the protocol of the International Germ Cell

Cancer Collaboration Group (IGCCG)^[6]. Post chemotherapy CT scan revealed that the tumor resolved with only small residual mass with tiny calcification, measuring 1.5 cm seen at the level of aortic bifurcation (Fig. 2a and 2b). The testicular lesion did not change when the US was repeated after chemotherapy (Fig. 2c). The patient was advised to have orchidectomy but he refused.

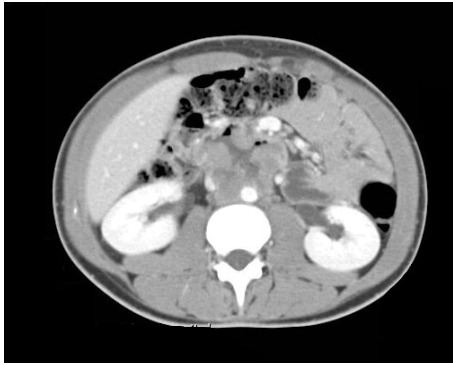


Fig. 2a. Prechemotherapy CT of the abdomen reveals soft tissue necrotic mass measuring 4.6 x 5cm in and is inseparable from the third part of the duodenum encasing the aorta, displacing and compressing the inferior vena cava.

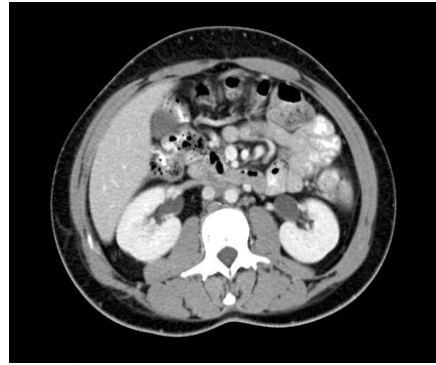


Fig. 2b. Postchemotherapy CT of the abdomen reveals that the tumor resolved.

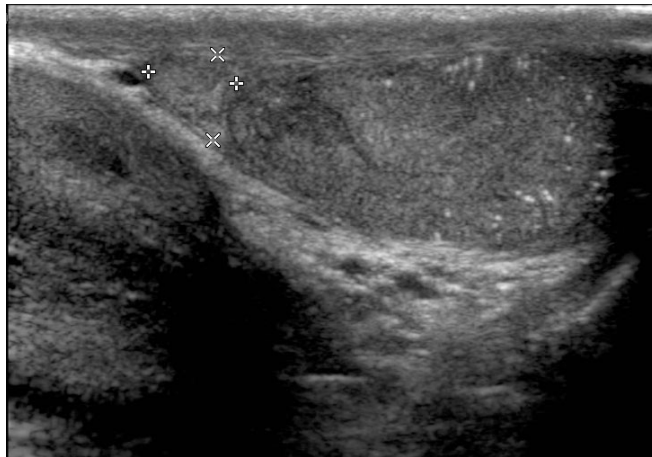


Fig. 2c. Scrotal ultrasound reveals an ill defined hypoechoic lesion of the upper pole of the right testicle, measuring around 1.0 x 1.2 cm.

Discussion

GCTs are the most common type of cancer in men age 15 to 35^[7]. Of GCTs that originate in the testis, 60% are nonseminomatous (NSGCTs)^[7]. Less than 10% of GCT arises from extragonadal primary site, usually in the mediastinum, retroperitoneum or pineal gland^[8]. Testicular cancer most commonly presents with a testicular mass, pain or hardness. One third of patients with testicular cancers may present with symptoms related to lung metastases and retroperitoneal lymphadenopathy. Symptoms of retroperitoneal metastases include low-back pain if there is abdominal mass^[3-4]. In a review by Chait *et al.* only 5% of patients with GCTs of the testis had GI metastasis of which the duodenum was the most commonly affected part of the intestine^[1]. Few cases have been reported with GI bleeding as the initial presenting feature of metastatic GCTs^[1,9-11].

NSGCTs are more likely metastasize to GI than seminoma^[5,12]. Invasion of duodenum by lymph node metastasis is more likely related to right-sided testicular tumor. The mode of spread to GI tract includes direct spread from involved paraaortic lymph nodes, hematogenous spread and peritoneal seeding^[13].

Recognition of GCTs in duodenum is very important because the management and prognosis is completely different from conventional primary duodenal adenocarcinoma. At the same time, the earlier the diagnosis can be made, the better the chances of the patient's response to therapy. Our case represents duodenal metastatic GCT which showed exclusively an embryonal carcinoma component, which mimics pathologically the primary adenocarcinoma and the differentiation between the two entities is very challenging.

The initial pathological diagnosis of the current case was duodenal poorly differentiated adenocarcinoma. Immunohistochemistry was very helpful in confirming the germ cell nature of this tumor. Primary duodenal adenocarcinomas are usually positive for EMA, and negative for PLAP, CD30 and OCT-4. Using multitumor tissue microarray, Looijenga *et al.*^[14] analyzed >100 different tumor categories and 3600 individual cancers plus demonstrated that OCT-4 (POU5F1) expression is very specific for particular subtypes of GCTs. Moreover, no protein was observed in the various tumors of nongerml cell origin including 64 intestinal adenocarcinoma; 17 of them small intestinal adenocarcinoma^[1].

OCT-4 is very specific for seminoma and embryonal carcinoma. In our case the morphology and the CD30 expression confirm the diagnosis of embryonal carcinoma.

In summary, the present study reports a rare duodenal metastatic embryonal carcinoma, which initially presents with an upper GI bleeding and a low-back pain. In young men with a malignant tumor in the upper GIT, the diagnosis of GCTs should be considered even in the absence of a palpable testicular mass. In addition, young men with low-back pain should be examined for testicular disease as well.

References

- [1] **Shariat SF, Duchene D, Kabbani W, Mucher Z, Lotan Y.** Gastrointestinal hemorrhage as first manifestation of metastatic testicular tumor. *Urology* 2005; **66**(6): 1319.
- [2] **Hansen KS, Sheley RC.** Aortoenteric fistula in advanced germ cell tumor: a rare lethal complication. *J Urol* 2002; **167**(5): 2131.
- [3] **Al Masri W, Alhendal A, Al Mishaan M.** A ruptured retroperitoneal germ cell tumor with invasion into the duodenum: a case report. *Gulf J Oncolog* 2007; **2**: 69-72.
- [4] **Cantwell BM, Mannix KA, Harris AL.** Back pain--a presentation of metastatic testicular germ cell tumours. *Lancet* 1987; **1**(8527): 262-264.
- [5] **Chait MM, Kurtz RC, Hajdu SI.** Gastrointestinal tract metastasis in patients with germ-cell tumor of the testis. *Am J Dig Dis* 1978; **23**(10): 925-928.
- [6] **[No authors listed].** International Germ Cell Consensus Classification: a prognostic factor-based staging system for metastatic germ cell cancers. International Germ Cell Cancer Collaborative Group. *J Clin Oncol* 1997; **15**(2): 594-603.
- [7] **Fléchon A, Rivoire M, Droz JP.** Management of advanced germ-cell tumors of the testis. *Nat Clin Pract Urol* 2008; **5**(5): 262-276.
- [8] **Bosl GJ, Motzer RJ.** Testicular germ-cell cancer. *N Engl J Med* 1997; **337**(4): 242-253.
- [9] **Fosado Gayosso M, Pérez Hernández JL, Bernal Sahagún F, Acevedo García C, Aguilar Ayala EL, Pérez Espinosa J.** Upper gastrointestinal bleeding as an initial manifestation of metastasis, secondary to a choriocarcinoma in a patient suffering from testicular mixed cell tumour. *Rev Esp Enferm Dig* 2011; **103**(1): 46-47.
- [10] **Bain AJ, Owens DJ, Savides TJ.** Image of the month. Upper gastrointestinal bleeding caused by metastatic testicular choriocarcinoma. *Clin Gastroenterol Hepatol* 2010; **8**(4): A22.
- [11] **Laiyemo AO, Jack M, Dawkins FW, Smoot DT.** Upper gastrointestinal bleeding from metastatic testicular cancer. *J Natl Med Assoc* 2009; **101**(8): 808-809.
- [12] **Johnson DE, Appelt G, Samuels ML, Luna M.** Metastases from testicular carcinoma. Study of 78 autopsied cases. *Urology* 1976; **8**(3): 234-239.
- [13] **Nord C, Fosså SD, Giercksky KE.** Gastrointestinal presentation of germ cell malignancy. *Eur Urol* 2000; **38**(6): 721-724.
- [14] **Looijenga LH, Stoop H, de Leeuw HP, de Gouveia Brazao CA, Gillis AJ, van Roozendaal KE, van Zoelen EJ, Weber RF, Wolffenbuttel KP, van Dekken H, Honecker F, Bokemeyer C, Perlman EJ, Schneider DT, Kononen J, Sauter G, Oosterhuis JW.** POU5F1 (OCT3/4) identifies cells with pluripotent potential in human germ cell tumors. *Cancer Res* 2003; **63**(9): 2244-2250.

النزف المعدي المعوي العلوي من سرطان الخصية الانتقالي

جوده أحمد المغربي، و جمال محمد زكري

قسم علم الأمراض، كلية الطب، جامعة الملك عبدالعزيز

قسم علم الأمراض و الأورام

مستشفى الملك فيصل التخصصي ومركز الأبحاث

جدة - المملكة العربية السعودية

المستخلص. على النقيض من سرطان الاثني عشر الابتدائية، فأورام الخلية الجنينية يمكن أن تكون قابلة للعلاج حتى عندما تكون منتشرة. ولذا فمن المهم للأطباء أن يكونوا على بينة من هذا الورم. نقدم حالة نادرة من سرطان جنيني منتشر والذي تسبب في البداية بنزيف الجهاز الهضمي العلوي. كان التعامل مع المريض بعلاجه بأربعة دورات من العلاج الكيماوي (بليوميسين، إيتوبوسيد، وسيسبلاتين) وكشفت عن وجود استجابة جيدة. نستنتج أنه عند الرجال الشباب مع وجود ورم خبيث في الجهاز الهضمي العلوي، ينبغي النظر في إمكانية تشخيص أورام الخلية الجنينية حتى في غياب كتلة الخصية.